



**PRESENTING CLINICAL SIGNS**

**DATE** History: Grade II/VI murmur. Coughing, wheezing. Previously diagnosed with stage B1 valvular disease and mild PH in October 2022.

7/7/23

**ECHOCARDIOGRAPHIC FINDINGS**

2D, M-mode, and Doppler study.

**PERFORMED BY:**

Kelly Vazquez

**INTERPRETED BY**

Keith Blass, DVM,  
MS, DACVIM  
(Cardiology)

Left atrial size is normal. The mitral valve leaflets are mildly thickened, and there is Doppler evidence of mitral regurgitation present. Left ventricular dimensions are normal. Left ventricular systolic function is hyperdynamic. The aorta and aortic valve are normal. Right atrial and right ventricular dimensions are normal. The tricuspid valve leaflets are mildly thickened, and there is Doppler evidence of tricuspid regurgitation present. TR velocity is consistent with the presence of mild pulmonary hypertension (PG 42 mmHg). The pulmonary artery and pulmonic valve are normal. No shunting lesions are visualized. No pericardial effusion or cardiac masses are seen. Pleural effusion is present.

**PATIENT**

Maui Sutherland

LA - 25.7 mm  
LVIDd - 25.7 mm  
LVIDs - 15.0 mm  
FS - 41.6%  
RA - 18.0 mm  
LVOT - 1.30 m/s  
RVOT - 0.76 m/s  
TR - 3.24 m/s

**SPECIES**

Canine

**ASSESSMENT/RECOMMENDATIONS**

Degenerative mitral and tricuspid valve disease  
Pulmonary hypertension

**BREED**

Min. Poodle Mix

This examination demonstrates no progression of Maui's valvular diseases or pulmonary hypertension over the past 9 months. Given that Maui does not have any cardiac chamber dilation and his pulmonary hypertension is mild, it appears unlikely that his current wheezing/coughing is cardiogenic in origin, though thoracic radiographs are recommended for further evaluation.

**SEX**

MN

No cardiac therapy appears to be indicated based on this exam (unless radiographs suggest a cardiac cause of Maui's current respiratory clinical signs).

**AGE**

14 y

A recheck echocardiogram is recommended in 6-9 months, sooner if new clinical signs compatible with cardiac dysfunction develop.

**WEIGHT**

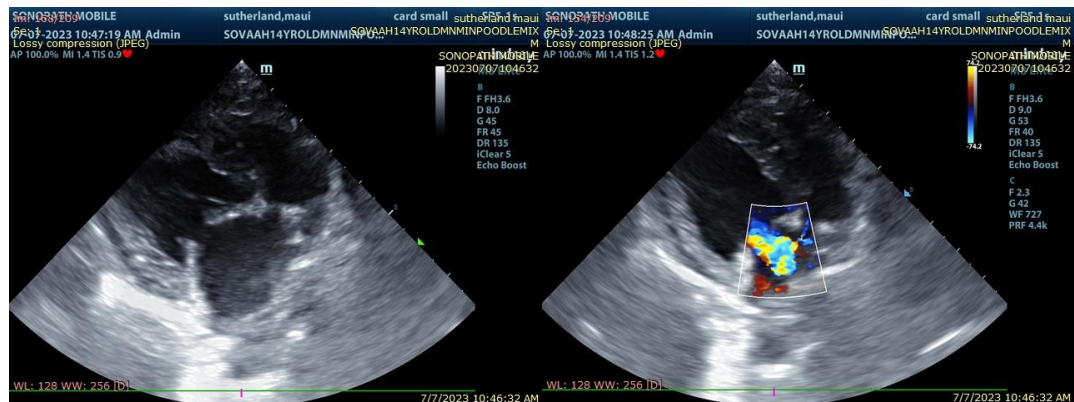13.5 lb

**HOSPITAL NAME**

Sova AH

**REFERRING VET**

Dr. Sova





DATE

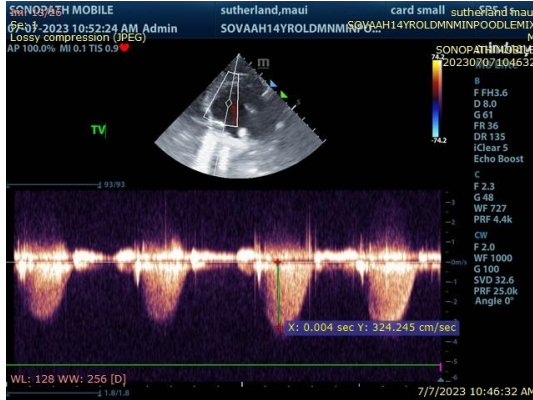
7/7/23

PERFORMED BY:

Kelly Vazquez

INTERPRETED BY

Keith Blass, DVM,  
MS, DACVIM  
(Cardiology)



PATIENT

Maui Sutherland

The information and recommendations provided are based on the images presented by the referring veterinarian. No evaluation can be communicated regarding pathology that was not visible in the image/video clips provided.

Thank you for this referral. If the clinical or image interpretation does not parallel your findings or if I can be of any further assistance please contact me.

SPECIES

Canine

Keith Blass, DVM, MS, DACVIM (Cardiology)  
KeithBlass@gmail.com  
631-804-5754

BREED

Min. Poodle Mix

SEX

MN

AGE

14 y

WEIGHT

13.5 lb

HOSPITAL NAME

Sova AH

REFERRING VET

Dr. Sova